

Composite Reduction Labiaplasty

Stefan Gress



Received: 5 September 2012 / Accepted: 27 April 2013 / Published online: 1 June 2013
© Springer Science+Business Media New York and International Society of Aesthetic Plastic Surgery 2013

Abstract

Background The demand for surgery to treat the external female genital area has increased significantly in recent years. Since 2001, the author and his colleagues have performed more than 2,100 surgical procedures to enhance the shape and function of the female genital area. The majority of these procedures were aimed at reduction of the labia minora. Drawing on the technique for labia minora reduction (labiaplasty) that the author first described in 2007 (Gress S, Gynäkologisch-Geburtshilfliche Rundschau 47:23–32, 2007), the technique was advanced such that in addition to an even reduction of the labia over their entire length (i.e., not only the part below the clitoris but also the part of the clitoral hood and above), it currently is possible to achieve further tightening of the clitoral hood and correction of a protruding clitoris (clitoral protrusion). This technique creates separate labial segments, the composition of which allows for an optimal shaping and reduction of the labia minora. Since 2006, the author and his colleagues have managed 812 cases using this technique, which has been named “composite reduction labiaplasty.”

Methods After removal of the excessive tissue in an S-shaped line along the internal and external aspects of the labium minus and after cutting of a cranial pedicle flap approximately 2–3 cm long (seen as the caudal extension of the clitoral hood), a crescent-shaped skin segment below the clitoris and a centrally pointed rectangular skin segment above the clitoral hood are removed. By joining the wound margins, a tightening and balanced reduction of the labia minora as well as a correction for the protruding tip of the clitoris (clitoral protrusion) is achieved.

Results All the patients received postoperative care and follow-up assessments during a period of 6 months. Except for a few cases of wound dehiscence requiring surgical correction, wound healing was without complications, and the outcomes were both aesthetically and functionally very satisfactory.

Conclusion In contrast to most techniques published to date, the “composite reduction labiaplasty” technique ensures a balanced reduction and a tightening of all parts of the labia minora, especially in the region of the clitoral hood. In addition, this technique results in an optimal correction of clitoris positioning in cases of clitoral protrusion. Concerns regarding impairment of sexual sensation or the ability to be sexually stimulated are unfounded. Approximately 35 % of the patients even reported a postoperative increase in their ability to be sexually stimulated.

Level of Evidence V This journal requires that authors assign a level of evidence to each article. For a full description of these Evidence-Based Medicine ratings, please refer to the Table of Contents or the online Instructions to Authors www.springer.com/00266.

Keywords Clitoral hood · Clitoral protrusion · Labia minora · Labia reduction · Labiaplasty

Hyperplastic labia minora often are associated with functional impairments or psychological distress. Many of the affected women feel embarrassed and therefore avoid being seen naked, even by their partner. In many cases, these women experience pain during sexual intercourse or sporting activities or while wearing tight clothing.

The exact details of what triggers this growth process of the labia minora are not known. A multifactorial etiology is assumed. Hormonal influences, genetic factors, aged-related changes, childbirth, the effects of gravity, and similar

S. Gress (✉)
Salvatorstrasse 3, Munich, Germany
e-mail: stefan.gress@plast-chirurgie.de;
gress@plast-chirurgie.de

factors may be among the causes underlying this condition [2].

No standard techniques for labia minora reduction have been established. In addition to the procedures described in the literature [3–14], several new techniques have recently emerged. Fundamentally, they all are based on a reduction of the labia minora in the part below the clitoris [2, 15–21]. None of these methods addresses the positional correction of clitoral protrusion.

Since we first published our technique in 2007 [1], we have tested and refined it by performing several hundred procedures. It now includes labial tissue reduction and removal of tissue located cranial or caudal to the clitoris. This creates separate segments composed in a way that enables a uniform reduction of the labia across their entire length, especially in the area of the clitoral hood, with additional correction of a protruding glans of the clitoris (clitoral protrusion) when indicated. However, with an operating time of approximately 2 h, this procedure is significantly longer than the methods described by others [2–7].

Patients and Methods

We first performed composite reduction labiaplasty in 2006. Since then, we have used it in 812 cases.

Functional problems (e.g., pain while wearing tight clothing or during sporting activities) were present in 27 % of the cases, whereas psychological distress resulting from the poor aesthetic appearance was present in 11 %. In most of the cases (62 %), the patients experienced both functional problems and psychological distress. No cases without any psychological or functional impairments were reported where decision to operate was based solely on aesthetic considerations (Fig. 1).

The aim of the surgical procedures is to achieve a result that best fulfills the wishes and expectations of the patients. Generally, the labia minora should be covered by the labia majora, if possible (Fig. 2). Reduction of the labia minora should result in an appearance that is as balanced as possible. That is, the reduction of the labia minora should not be limited to the area below the clitoris but should include the region of the clitoris and above it. This anatomic region imposes special requirements on the surgical technique. On the one hand, this region is exposed to significant mechanical stress and also is prone to wound-healing complications resulting from the chronically moist environment. On the other hand, strong sutures cannot be used due to the delicate nature of the tissue and the subtle modeling required. Therefore, fine sutures and narrow stitches should generally be used.

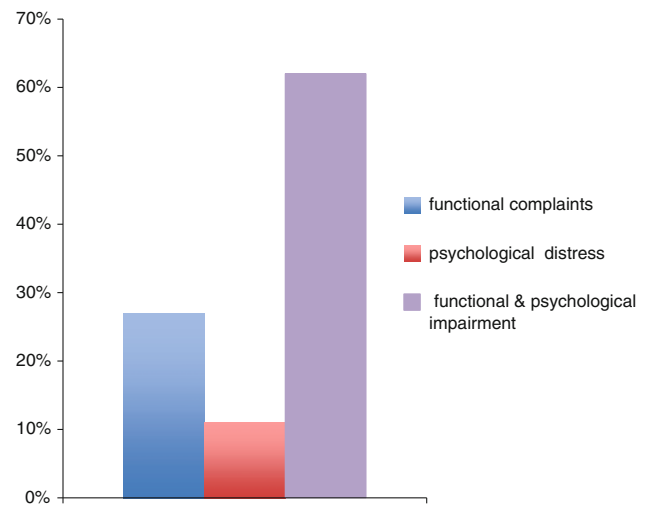


Fig. 1 For most of the patients, hypertrophy of the labia minora caused both functional problems and psychological distress

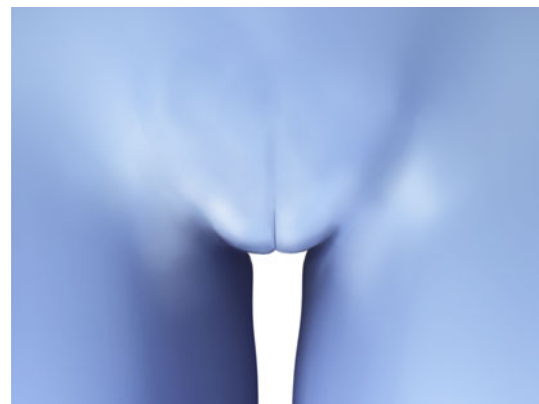


Fig. 2 The aim of surgery was to achieve coverage of the labia minora by the labia majora

In the preoperative analysis, the position of the clitoral body, especially the glans of the clitoris, should be taken into account. Although the clitoral hood usually is involved in hyperplasia of the labia minora, a clitoral protrusion (i.e., glans of the clitoris protruding above the level of the labia majora) is a common additional finding (Fig. 3). In these cases, correction of the clitoris position should be considered from an aesthetic perspective.

In all the cases we managed, the procedure was performed on an outpatient basis, usually with the patient under local anesthesia. To prevent surgery-site infection, the patients received a broad-spectrum antibiotic in addition to oral analgesics. The local anesthetic used was a mixture of 1 % lidocaine and 0.5 % Carbostesin, with the addition of Suprarenin (epinephrine) at a concentration of 1:100,000. The pubic hair was completely removed. Instead of a scalpel for the skin incision or for cutting along the incision line, we used a radiofrequency surgical device

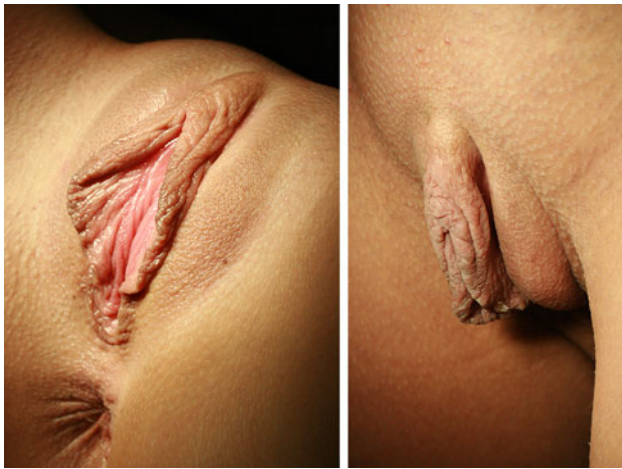

Fig. 3 a, b Patient with hypertrophy of the labia minora and clitoral protrusion

(30 W). This allowed for precise tissue incision without the need for tensioning.

The curved line of the incision runs caudally along the internal aspect of the labium minus toward the clitoris until it reaches the frenulum, which extends into the clitoris. The frenulum is preserved as a caudally pointed triangular process approximately 3 mm long. The line of the incision then turns caudally again and cuts a cranial pedicle flap approximately 2–3 cm long with a rather narrow base.

To avoid vascular compromise at the tip of the flap, it should be ensured that an adequate amount of subcutaneous tissue is preserved beneath the flap. At the tip of the flap, the line of incision turns cranially, medially, and parallel to the fold of the labia majora (Fig. 4). Subsequently, the incision turns at the upper origin of the fold caudally again and runs in an S-shaped line along the external aspect of the labium minus, where it finally meets the starting point of the incision line (Fig. 5). The excessive tissue then can be removed. The height of the labial ridge should not exceed 1–0.8 cm.

Next, a crescent-shaped skin segment is removed from below the clitoris. The extent to which the tip of the clitoris is shifted caudally is determined by the width of this segment. Subsequently, a centrally pointed rectangular skin segment located cranial to the clitoris is removed (Figs. 6, 7, 8).

After this resection, three separated segments are present, which are joined. First, the cranial segments are joined. A subcutaneous 5-0 Vicryl suture placed in the middle is sufficient for loose approximation of the wound edges. Skin closure is performed with interrupted 6-0 Vicryl sutures. For the subsequent closure of the segment below the clitoris, interrupted 5-0 Vicryl sutures are used because monofilament sutures may cause painful postoperative irritation of the clitoris.

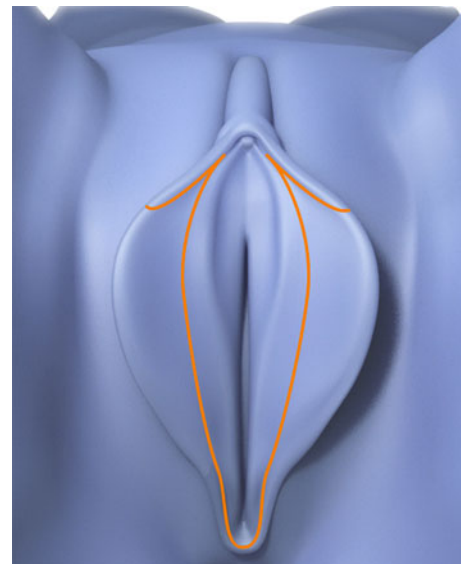


Fig. 4 Incision line (orange) along the internal aspect of the labium minus

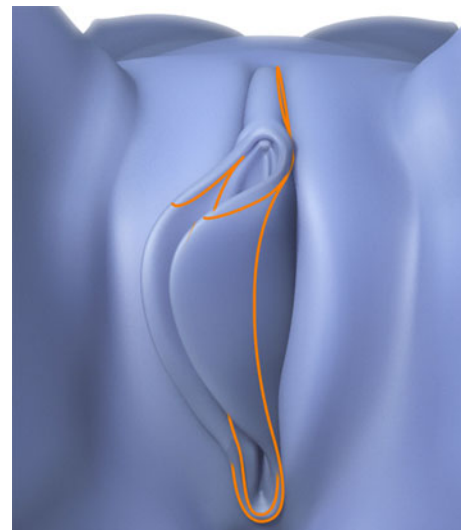


Fig. 5 Incision line (orange) along the external aspect of the labium minus

To prevent postoperative bleeding, the subcutaneous tissue below the clitoris is closed along the entire course by means of a 5-0 Vicryl continuous suture. The two lateral flaps then are integrated into the line of the labia minora using moderate tension followed by deep tissue fixation (Figs. 9, 10). The tension of the flaps is primarily responsible for the degree of clitoral hood tightening.

Next, the medial and lateral layers of each labium minus are separated using scissors and placed without tension around the distal processes of the flaps. This prevents the tension of the flaps from being transferred to the labia, where it could cause labial distortion. Depending on the

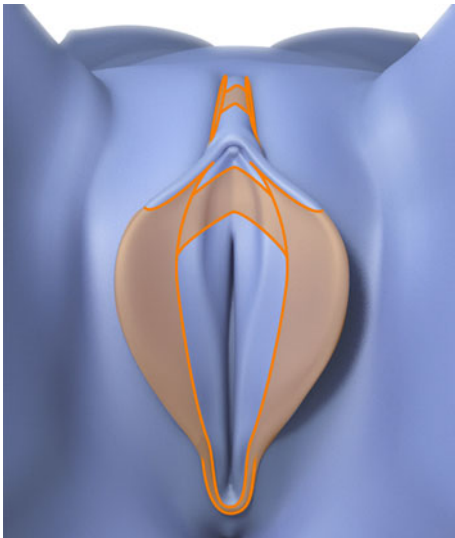


Fig. 6 Orange marked areas are removed

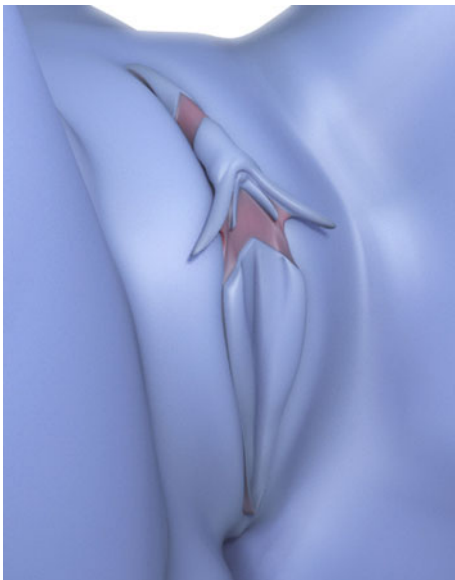


Fig. 7 Oblique view after tissue removal (area marked red)

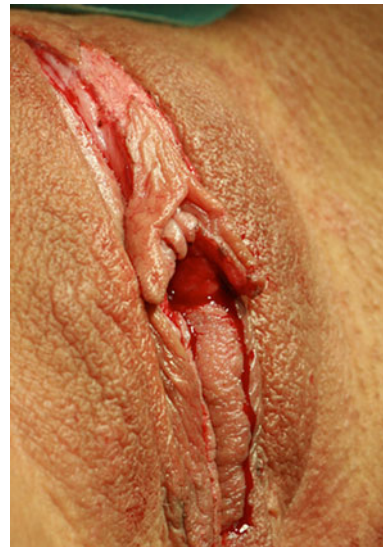

Fig. 8 Oblique view after tissue removal. Patient lying

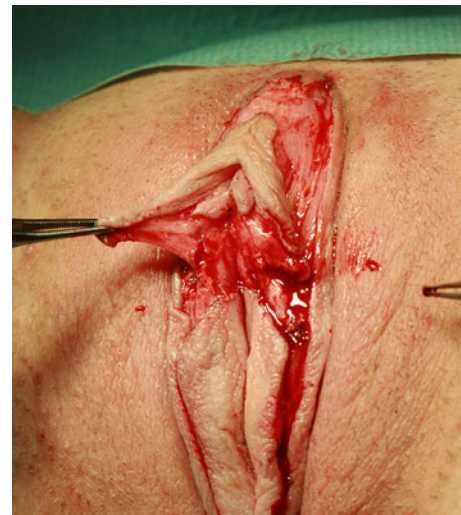


Fig. 9 Forceps elevating the tight flap. Note the amount of subcutaneous tissue preserved

patient's wishes, the labia can be modeled to have either a straight or a slightly curved shape (Fig. 11). Where the layers of the labia cover the tips of the flaps, their epithelium is removed.

The principal closure is performed using a 6-0 Monocryl suture. To shape, erect, and stabilize the labial ridge, it is important to place isolated mattress sutures at the labial base along the segment below the clitoris using 5-0 Vicryl at close intervals. The knots should be located at the medial aspect (Fig. 12). After surgery, the length of the labias should be reduced to the amount planned; the clitoral hood should be tightened; and the clitoris should migrate into the level of the labia majora (Figs. 13, 14, 15).

Results

Data were collected using an anonymous questionnaire sent to the patients by mail. Only the patients who underwent this procedure at least 6 months before the survey were contacted in this way. In addition, all the patients were followed up postoperatively.

Both overall satisfaction with the outcome of the procedure and rating of the achieved aesthetic result were classed at a very high level, with an average score of 9.4 out of 10 possible points (Fig. 16). Functional problems were completely resolved in 92.3 % of the cases, whereas psychological distress was completely relieved for 89.7 %

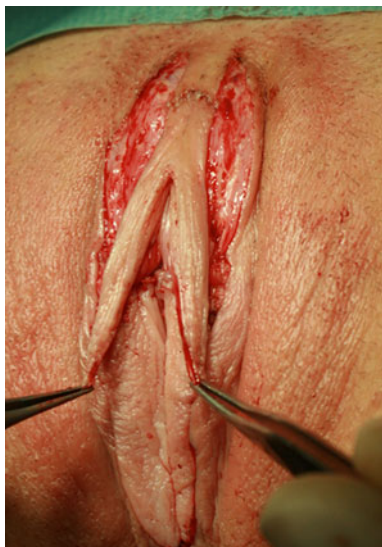

Fig. 10 Integration of the two lateral flaps into the line of the labia minora by moderate tension

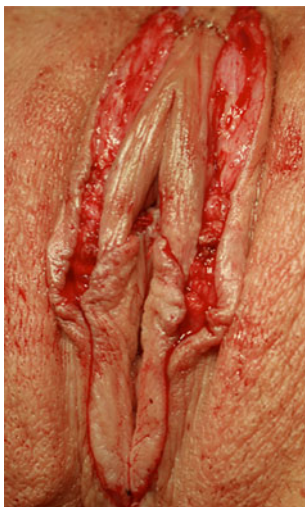

Fig. 11 Tensionless placement of the internal and external layers of the labium minus around the flap allowing the shape of the labium to be modeled

of the patients. At least an improvement of symptoms was reported for functional problems in 6.4 % of the cases and for psychological symptoms in 8.1 %. No improvement of functional problems was reported by 2.2 % of the patients, whereas 1.3 % rated the psychological distress as unchanged. None of the patients reported a worsening of functional or psychological problems (Fig. 17).

Postoperative pain was present for approximately 24 h after the procedure on the average. In a few cases, patients reported pain and a burning sensation up to 4 days after the procedure. Three patients reported pain during intercourse over a period of 2 months, with this problem disappearing again. None of the patients reported problems with sexual

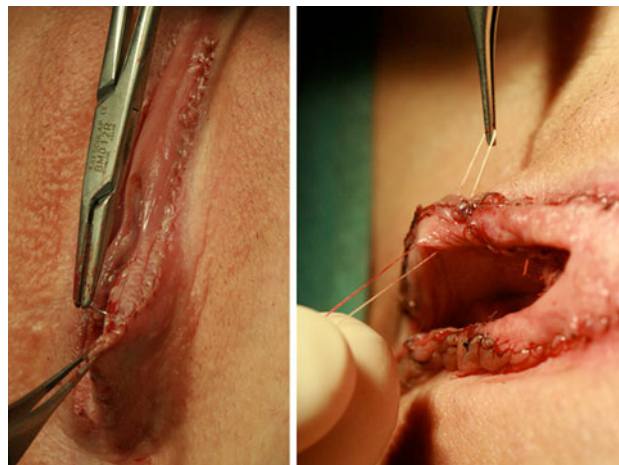


Fig. 12 a, b Along the segment below the clitoris, isolated mattress sutures erect and stabilize the labial ridge

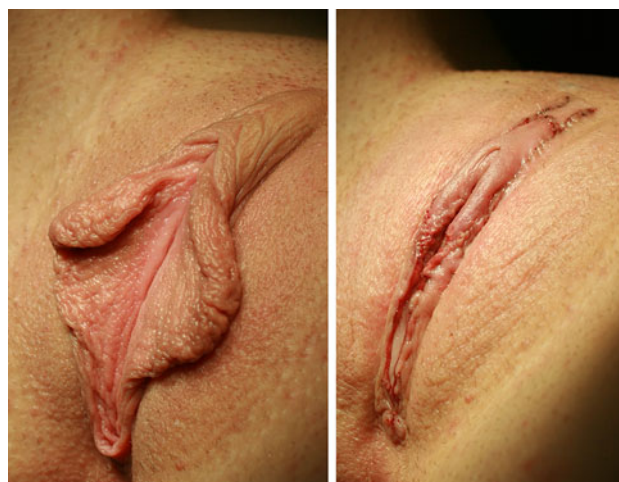

Fig. 13 a, b Views before and after completion of surgery showing a tightened clitoral hood, migration of the clitoris to the level of the outer labia, and shortening of the labia along their entire length

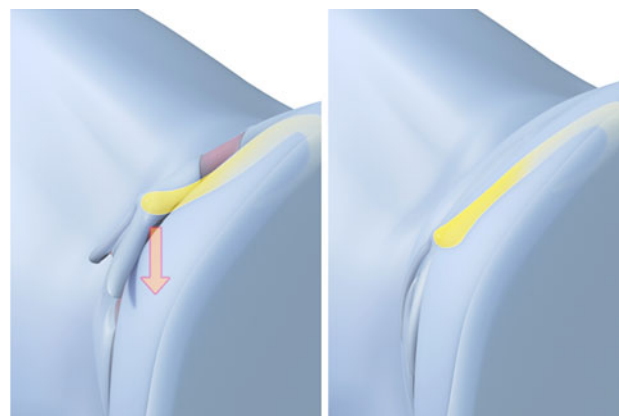


Fig. 14 a, b Views showing the caudal migration of the clitoris

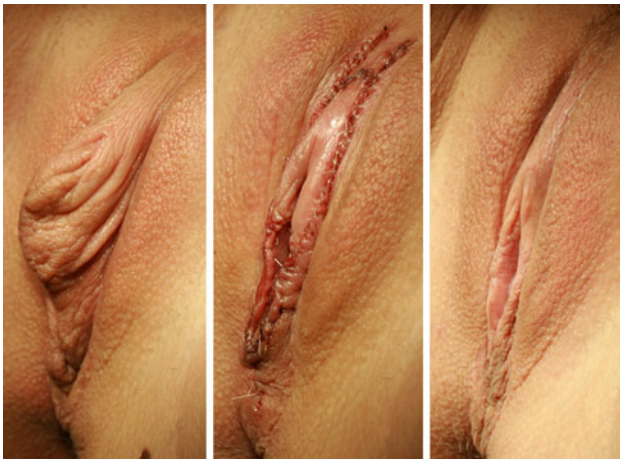

Fig. 15 a–c Views before surgery, directly after surgery, and 6 months postoperatively

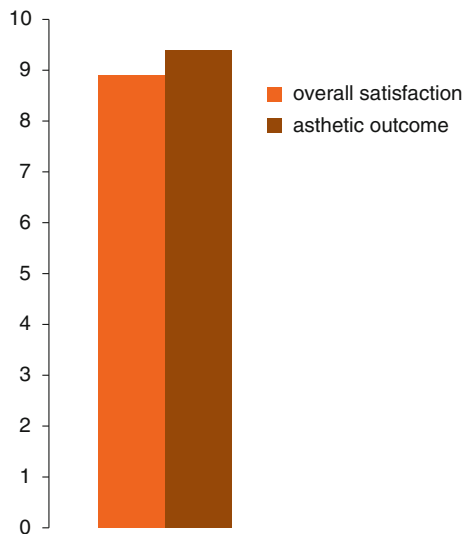


Fig. 16 High rating of the achieved result in terms of overall satisfaction and aesthetic outcome

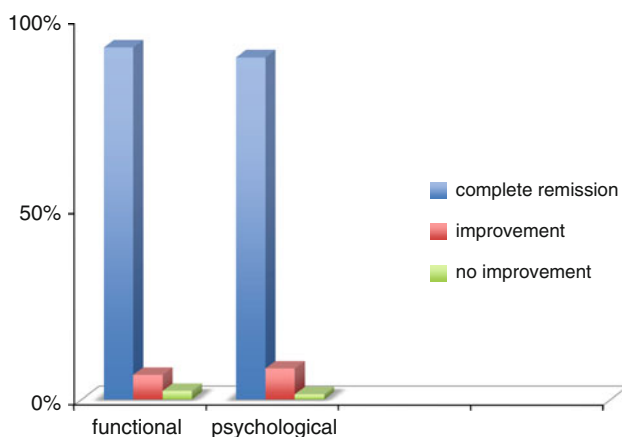


Fig. 17 In most of the cases, functional and psychological impairments were completely resolved

stimulation. In approximately 35 % of the cases, sexual excitability was increased after the procedure.

A total of 6.4 % of the patients experienced wound-healing complications requiring surgical revision, and in approximately seven cases, postoperative bleeding requiring surgical treatment occurred. Asymmetric outcomes necessitating adjustment were seen in 2.3 % of the cases. For 4.2 % of the patients, we performed an additional secondary resection because the desired labial length had not been achieved. In none of the cases was necrosis or wound-healing disturbance observed. There also was no case of infection. Unsightly or hypertrophic scarring did not occur in any of the cases. Mild asymmetric outcomes were surgically corrected in 3.6 % of the cases.

Discussion

The demand for functional and aesthetic surgical correction procedures performed on the female genital region has significantly increased in Germany and many other Western countries over recent years. In our practice alone, we have performed more than 2,150 such procedures since 2001, including 1,763 reductions of the labia minora.

We do not believe that “intimate surgery,” as this field often is termed in the media, is just a passing fashion. We believe it is rather a consequence of a more open approach to female sexual behavior. There are two reasons for this. First is women’s recognition of their own anatomic shortcomings based solely on the fact that the current abundance of photos picturing female genitals, (e.g., on the Internet and in the media) promotes direct comparison with other women. A significant contributing factor is the trend to shave the genital region. The second reason is the awareness raised by the media that these shortcomings can be addressed, combined with the expectation of ability to experience free and unrestricted sexuality.

We performed the first labia minora reductions using the techniques published at that time [3, 8]. Although the results achieved represented some improvement, they often did not meet the expectations of the patients who anticipated that the labia minora would be completely covered by the labia majora over their entire length, not only in the section below the clitoris, which is the best outcome achievable with these techniques and the techniques published to date [2–21]. However, especially in cases of clitoral protrusion, an isolated reduction of the labia minor only below the clitoral level often leads to unsatisfactory aesthetic results that are hard to correct (Fig. 18).

Taking into account the fact that in cases of labial hypertrophy, the labia typically are enlarged over their entire length, including the area around and above the clitoris, and that a reduction limited to the area below the

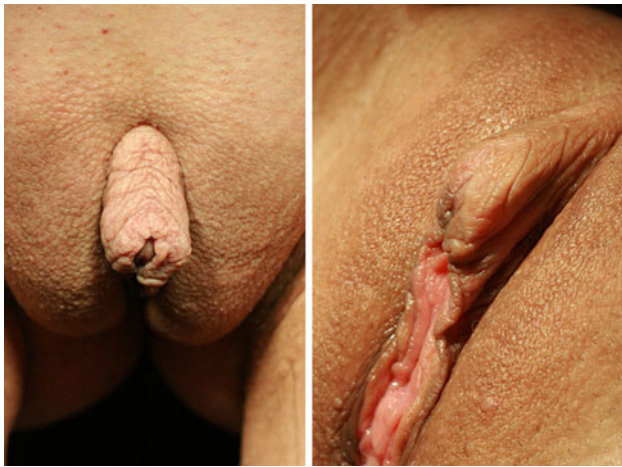

Fig. 18 Typical deformity after surgery with labia reduction limited caudal to the clitoris, no correction of clitoral protrusion, and no tightening of the clitoral hood

clitoris usually appears as incomplete, we developed a technique intended to achieve reduction of the labia minora over their entire length [1], thereby permitting an overall balanced result.

With our technique, no skin is removed above or below the clitoris. Only Burow's triangles are resected at the inner aspect of the labium minus before integration of the lateral flaps to avoid engorgement of skin. We currently use this technique for cases in which no additional tightening of the clitoral hood is necessary or no protrusion of the clitoris needs to be corrected (Fig. 19).

Until 2004, approximately 900 procedures were performed using the aforementioned technique. Although patients were very satisfied with the aesthetic results achieved, they often desired a more pronounced tightening of the clitoral hood and wanted the area of the clitoris more completely covered by the labia majora.

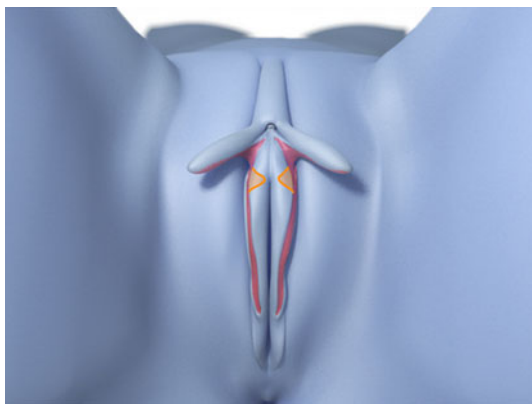


Fig. 19 When no clitoral protrusion is to be corrected and no additional tightening of the clitoral hood needs to be performed, Burow's triangles are removed at the inner aspect of the labium minus before integration of the lateral flaps

In response to these requests, we advanced this technique to include an additional tightening of the clitoral hood in a cranial direction and the option to correct clitoral protrusion. The additional resection of skin segments above and below the clitoris after resection of the hypertrophic labia minora over their entire length creates separate segments composed (therefore the term “composite” was chosen) to allow for additional tightening of the clitoral hood and correction of clitoral protrusion to achieve the best possible overall result (Figs. 20, 21, 22, 23, 24, 25, 26).

Patients often mistake a genuine hypertrophy of the glans of the clitoris for a hypertrophy of the clitoral hood (preputium) or a protrusion of the tip of the clitoris. Cases involving true hypertrophy of the clitoris are rare. In most cases, hypertrophy of the labia minora is associated with clitoral hood hypertrophy, which in turn often is accompanied by a protruding tip of the clitoris. When reduction of the labia minora results in the hood sitting tightly on the clitoris, a clitoral protrusion previously covered by the excessive tissue may become more prominent than it was before the surgical correction. Therefore, the position of the clitoris must be assessed during the initial consultation, and the patient should be informed about it and the options for correction.

In cases involving a protruding glans of the clitoris, the glans can be easily shifted caudally by wound-edge fusion after removal of a tissue crescent below the clitoris, causing the tip (glans) of the clitoris to bend downward in the sagittal and transversal planes, thus eliminating the protrusion. A distance of at least 1.5 cm to the external urethral orifice must be ensured to avoid a potentially permanent deviation of the urinary stream. The distance between the clitoris and the urethral orifice varies significantly among women. Correction of clitoral protrusion by means of caudal tightening is not possible if the urethral orifice is too close to the clitoris.




Fig. 20 Patient 1. Postoperative results. Frontal view, standing



Fig. 21 Patient 1. Postoperative results. Oblique view, lying

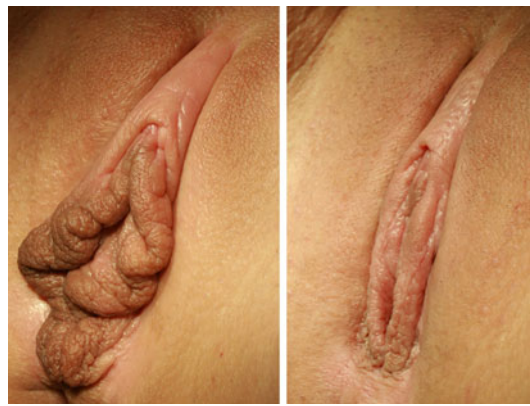

Fig. 24 Patient 2. Postoperative results. Oblique view, lying

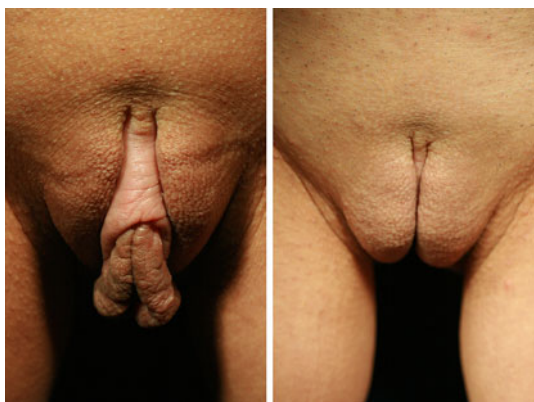


Fig. 22 Patient 2. Postoperative results. Frontal view, standing

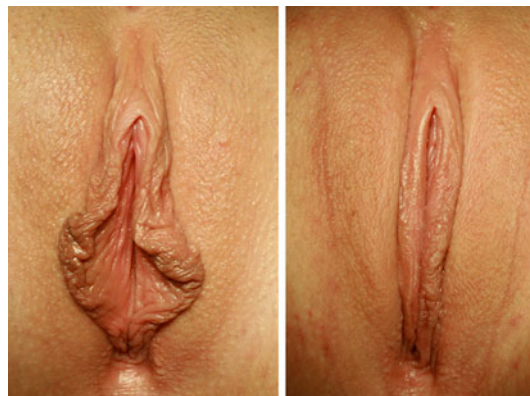

Fig. 25 Patient 3. Postoperative results. Frontal view, lying

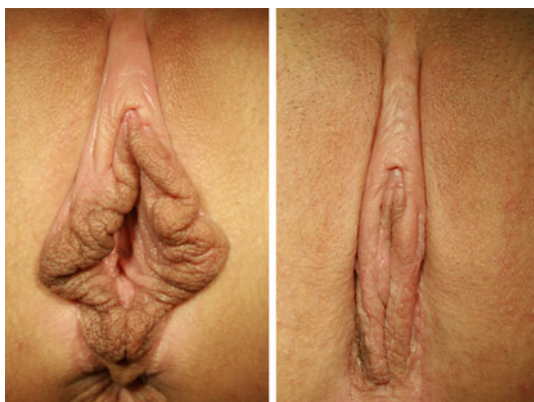

Fig. 23 Patient 2. Postoperative results. Frontal view, lying

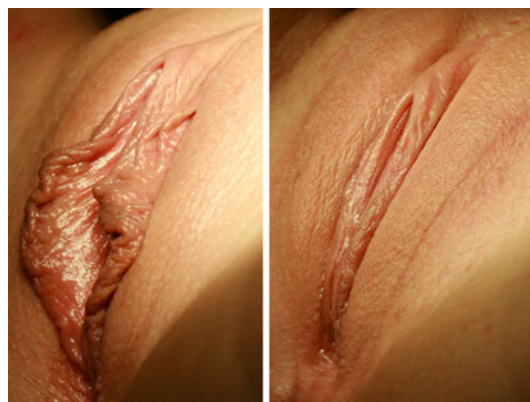

Fig. 26 Patient 3. Postoperative results. Oblique view, lying

Shifting the clitoris closer to the vaginal introitus might result in a stronger stimulation of the clitoris during intercourse. Although patients find this agreeable, this issue should be addressed during the informed consent discussion.

The slight tension on the lateral flaps, which anatomically represent the caudal extensions of the clitoral hood, ensures optimal tightening of the clitoral hood, whereas in

the segment below, tension-free approximation of the now shortened layers of the labia minora can be achieved.

The “running W” line of incision along the labia minora crest described by Maas and von Haage [11, 12] is not required given that the significant folding of the skin makes the development of scarring and contractures unlikely. Additional tightening of the clitoral hood is achieved with closure of the cranial skin segments. If no additional

tightening of the clitoral hood is necessary, no removal of skin cranial to the clitoris is required. However, when it is performed, excessive cautery should be avoided to avert damage to the clitoral nerves seated below [22–26].

Rouzier et al. [14] have recommended critically evaluating the indication for labia minora reduction if their height is less than 4 cm. We do not share this view because we believe that the patient ultimately must evaluate any existing psychological or functional complaints, resulting in more liberal indications for this procedure. However, we follow the recommendations of Hodgkinson and Hait [8] to avoid a labial height of less than approximately 1 cm.

The general satisfaction with the overall result achieved in our cases was very high. Functional and psychological impairments usually disappeared after the procedure. The positive evaluation of both the aesthetic and the functional results with a score of 9 out of 10 points justifies the rather high surgical effort associated with the use of this technique.

Complications were rare, and the postoperative course usually was without problems. Most frequently, wound-healing complications and suture dehiscence were observed, especially in the area of the fusion point of the lateral flaps in the line of the labial ridge. In this area, careful attention should be paid to a precise and tension-free approximation of the wound edges. Hematoma or secondary bleeding requiring revision surgery occurs only very rarely if a continuous subcutaneous wound closure is performed.

We believe the observation that no wound infection occurred in any of the cases is mainly due to the excellent blood supply of genital tissue and the routine administration of a broad-spectrum antibiotic. Postoperative pain usually subsides after 1–2 days and can be managed well with medication.

The fact that no noticeable, painful, or hypertrophic scars developed for any of the patients and that no cases of disturbed sexual sensations or dysaesthesias were reported invalidates the concerns of critics. To the contrary, we observed an improvement of sexual excitability in approximately 35 % of the cases, especially among the patients who underwent correction of clitoral protrusion. This can be explained by the fact that with the clitoris positioned closer to the vaginal introitus, it is exposed to more direct stimulation.

The reported procedure is not indicated if the only reason for shifting the position of the clitoris is related to stimulation issues. Although sexual stimulation improvements were observed, the reported percentage is too low for a conclusion that such improvements alone are sufficient to justify this procedure.

The indication also should be viewed critically for patients whose reluctance to comply with the necessary

postoperative physical rest can be expected because in such cases, the risk of wound-healing complications is much higher. For adolescents younger than 18 years, the question whether the procedure should be performed or not must be discussed together with the parents. We agree that the procedure is indicated for under-aged patients only if the physical findings are marked and likely to affect the sexual development of the girl.

Conclusion

Since 2006, we have performed “composite reduction labiaplasty” for approximately 800 patients. The technique allows for delicate modeling and optimal tightening of the labia minora over their entire length. The low rate of postoperative complications and the high level of satisfaction with the functional and aesthetic results encourage a liberal indication for the procedure and justify the comparatively higher surgical effort required compared with other techniques.

Conflict of interest The author declares that he has no conflicts of interest to disclose.

References

- Gress S (2007) Ästhetische und funktionelle Korrekturen im weiblichen Genitalbereich. *Gynäkologisch-Geburtshilfliche Rundschau* 47:23–32
- Kruk-Jeromin J, Zielinski T (2010) Hypertrophy of labia minora: pathomorphology and surgical treatment. *Ginekol Pol* 81:298–302
- Alter G (1998) New technique for aesthetic labia minors reduction. *Ann Plast Surg* 40:287–290
- Chavis WM, LaFerla JJ, Niccolini R (1989) Plastic repair of elongated, hypertrophic labia minors: a case report. *J Reprod Med* 34:373
- Choi HY, Kim KT (2000) A new method for aesthetic reduction of labia minors (the deepithelialized reduction labiaplasty). *Plast Reconstr Surg* 105:419
- Gilbert DA (1999) Female aesthetic genital surgery. In: Ehrlich RM, Alter GJ (eds) *Reconstructive and plastic surgery of the external genitalia*. WB Saunders Co., Philadelphia, p 471
- Giraldo F, González C, De Haro F (2004) Central wedge nymphectomy with a 90-degree Z-Plasty for aesthetic reduction of the labia minors. *Plast Reconstr Surg* 113:1820
- Hodgkinson DJ, Hait G (1984) Aesthetic vaginal labiaplasty. *Plast Reconstr Surg* 74:414
- Honore LH, O'Hara KE (1978) Benign enlargement of the labia minora: report of two cases. *Eur J Obstet Gynecol Reprod Biol* 8:61
- Laub D (2000) A new method for aesthetic reduction of labia minors: the deepithelialized reduction labiaplasty (discussion). *Plast Reconstr Surg* 105:423
- Maas SM, Hage JJ (1998) Aesthetic labia minors reduction. *Ann Plast Surg* 41:685
- Maas SM, Hage JJ (2000) Functional and aesthetic labia minors reduction. *Plast Reconstr Surg* 105:1453

13. Radman HM (1976) Hypertrophy of the labia minora. *Obstet Gynecol* 48(Suppl):78
14. Rouzier R, Louis-Sylvestre C, Paniel BJ, Haddad B (2000) Hypertrophy of labia minora: experience with 163 reductions. *Am J Obstet Gynecol* 182:35–40
15. Krizko M, Krizko M, Janek L (2005) Plastic adjustment in hypertrophy of labia minora (Slovak). *Ceska Gynekol* 70: 446–449
16. Trichot C, Thubert T, Faivre E, Fernandez H, Deffieux X (2011) Surgical reduction of hypertrophy of the labia minora. *Int J Gynaecol Obstet* 115:40–43
17. Miklos JR, Moore RD (2008) Labiaplasty of the labia minora: patients' indications for pursuing surgery. *J Sex Med* 5: 1492–1495
18. Solanki NS, Tejero-Trujeque R, Stevens- King A, Malata CM (2010) Aesthetic and functional reduction of the labia minora using the Maas and Haage technique. *J Plast Reconstr Aesthet Surg* 63:1181–1185
19. Ellsworth WA, Rizvi M, Lypka M, Gaon M, Smith B, Cohen B, Dinh T (2010) Techniques for labia minora reduction: an algorithmic approach. *Aesthet Plast Surg* 34:105–110
20. Miklos JR, Moore RD (2012) Postoperative cosmetic expectations for patients considering labiaplasty surgery: our experience with 550 patients. *Surg Technol Int* 21:170–174
21. Cao YJ, Li FY, Zhou CD, Hu JT, Ding J, Xie LH, Li (2012) A modified method of labia minora reduction: the deepithelialised reduction of the central and posterior labia minora. *J Plast Reconstr Aesthet Surg* 65(8):1096–1102
22. O'Connell HE, Sanjeevan KV, Huston JM (2005) Anatomy of the clitoris. *J Urol* 174:1195–1198
23. Papageorgiou T, Hearn-Stokes R, Peppas D, Segars JH (2000) Clitoroplasty with preservation of neurovascular pedicles. *Obstet Gynecol* 96:821–836
24. Platzer W (1985) *Atlas of topographical anatomy*. Thieme Stuttgart, New York, pp 302–307
25. Shaw A (1992) Subcutaneous reduction clitoroplasty. *J Pediatr Surg* 12:331–338
26. Malionovsky L, Sommerova J, Martincik J (1975) Quantitative evaluation of sensory nerve endings in hypertrophy of labia minors pudendi in women. *Acta Anat* 92:129