

# Outcomes of Polydioxanone Knotless Thread Lifting for Facial Rejuvenation

DONG HYE SUH, MD, PhD,\* HEE WON JANG, MD,† SANG JUN LEE, MD, PhD,\*  
WON SEOK LEE, MD,‡ AND HWA JUNG RYU, MD, PhD†

---

**BACKGROUND** Thread lifting is a minimally invasive technique for facial rejuvenation. Various devices for thread lifting using polydioxanone (PDO) are popular in aesthetic clinics in Korea, but there have been a few studies regarding its use.

**OBJECTIVE** To describe PDO thread and techniques adopted to counteract the descent and laxity of the face.

**METHODS** A retrospective chart review was conducted over a 24-month period. A total of 31 thread lifting procedures were performed. On each side, 5 bidirectional cog threads were used in the procedure for the flabby skin of the nasolabial folds. And, the procedure was performed on the marionette line using 2 twin threads.

**RESULTS** In most patients (87%), the results obtained were considered satisfactory. Consensus ratings by 2 physicians found that objective outcomes were divided among “excellent,” “good,” “fair,” and “poor.” Texture wise, the outcome ratings were 13 as excellent and 9 as good. Lifting wise, ratings were 11 as excellent and 6 as good. The incidence of complications was low and not serious.

**CONCLUSION** Facial rejuvenation using PDO thread is a safe and effective procedure associated with only minor complications when performed on patients with modest face sagging, fine wrinkles, and marked facial pores.

*The authors have indicated no significant interest with commercial supporters.*

---

The process of aging changes the shape, texture, and color of the face. Facial shape is mainly transformed by uneven descent and laxity of the skin and soft tissues. Texture is primarily determined by fine wrinkles and pores of the skin.<sup>1,2</sup>

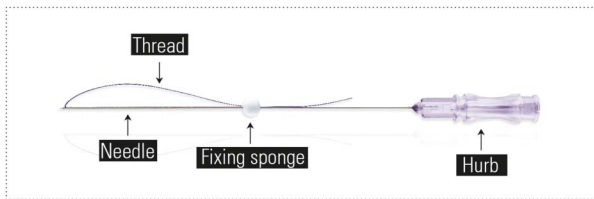
Recently, there has been a growing trend for patients to pursue minimally invasive treatments with reduced risk of side effects and downtime to correct wrinkles and laxity.<sup>3</sup> A number of procedures have been tried over the past few decades to improve the appearance of a slack face without surgery.<sup>4</sup>

The evolution of thread lifting techniques and their application in the field of aesthetic procedure is now in its third decade.<sup>5</sup> Since Sulamanidze proposed procedures for lifting and rejuvenating facial tissues by means of Aptos threads in 1998, various techniques have been introduced, including Woffles thread lifting, Waptos suture lifting, Isse unidirectional barbed threads lifting, and silhouette lifting.<sup>2,6–8</sup> However, some patients dislike the idea of insertion of nonabsorbable threads that remain permanently in the facial soft tissue. For that reason, new, absorbable, barbed suture designs have become available.<sup>5,9</sup>

\*Department of Dermatology, Arumdaun Nara Dermatologic Clinic, Seoul, Republic of Korea; †Department of Dermatology, Korea University College of Medicine, Seoul, Republic of Korea; ‡Department of Plastic Surgery, Gold Plastic Surgical Clinic, Seoul, Republic of Korea

*Supported by a Korea University Grant.*

© 2015 by the American Society for Dermatologic Surgery, Inc. Published by Wolters Kluwer Health, Inc. All rights reserved.  
ISSN: 1076-0512 • Dermatol Surg 2015;41:720–725 • DOI: 10.1097/DSS.0000000000000368



**Figure 1.** Schematic figure of knotless PDO thread device.

In this study, the authors analyzed a new absorbable lifting device using polydioxanone (PDO). The aim of this study was to describe the efficacy and safety of PDO knotless thread lifting for facial rejuvenation.

**Materials and Methods**

A retrospective chart review was performed for patients who underwent thread lifting with PDO from April 2012 to March 2014 in Arumdaun Nara Dermatologic Clinic and Gold Plastic Surgical Clinic in Korea. The authors reviewed gender, age, and pre-operative and postoperative clinical digital photographs. The results were assessed objectively using serial digital photography and subjectively according to patient self-evaluation. The principles of the 1975 Declaration of Helsinki were followed.

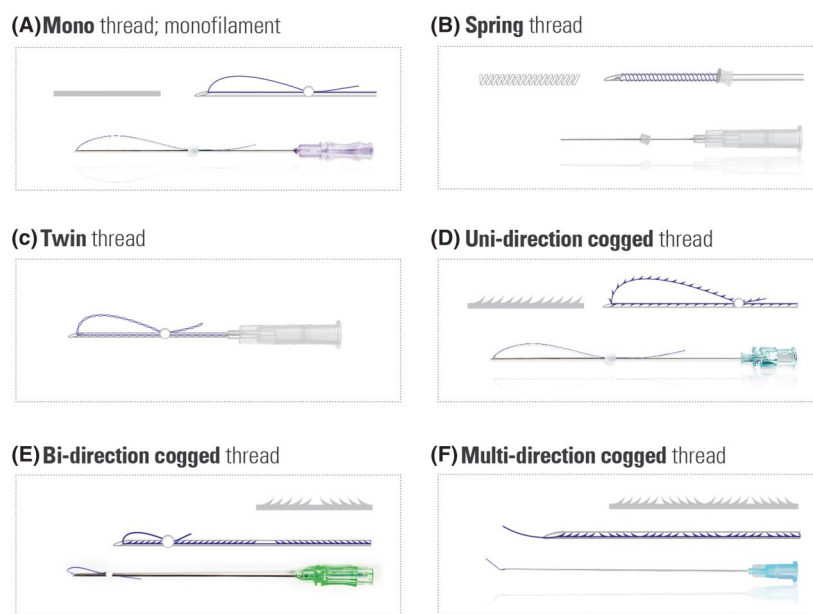
For the objective assessment, 2 physicians not involved in the procedures reviewed the outcomes based on

serial digital photography. The outcomes were divided among “excellent,” “good,” “fair,” and “poor.” The patients were followed after thread lifting, and their level of satisfaction was self-evaluated according to the scale of “excellent,” “good,” and “unsatisfied.” All statistical analyses were conducted using PASW version 18.0 (IBM, Armonk, NY). Descriptive statistics are shown as both numbers and percentages of patients or as mean values and standard deviations. Ratings of skin texture improvement and lifting were compared by the Mann–Whitney *U* test.

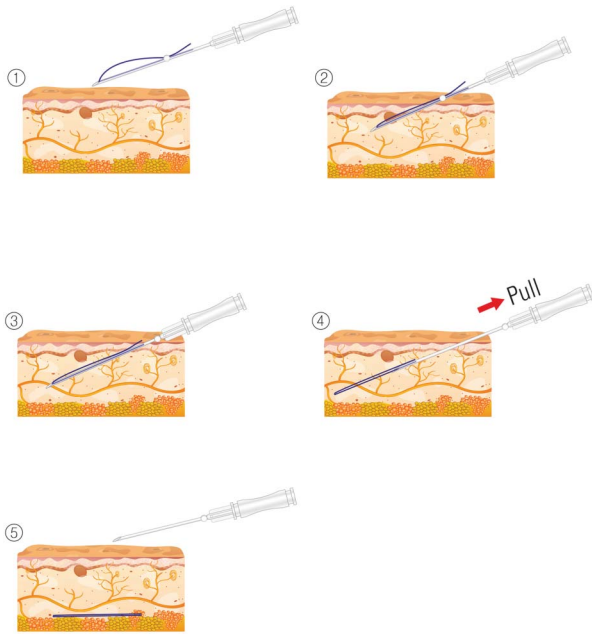
**Polydioxanone Threads**

A schematic figure of the knotless PDO thread device is presented in Figure 1. Polydioxanone threads for facial rejuvenation can be categorized into 3 different types. Mono PDO thread is monofilament, nonbarbed, and thin (0.07–0.15 mm). Spring or twin thread, made from a twined single monofilament or 2 monofilaments braided, is more tensile than mono PDO thread. Cog PDO thread has barbs, which cling to tissues for lifting effects when inserted. Depending on the direction of the spikes, cog PDO thread is categorized as unidirectional, bidirectional, or multidirectional (Figure 2).

The thread, when inserted to a needle, forms a V-shape with an inner half inserted in the caliber



**Figure 2.** Various knotless PDO thread devices. (A) Mono thread, (B) Spring thread, (C) Twin thread, (D) Uni-direction cogged thread, (E) Bi-direction cogged thread, and (F) Multi-direction cogged thread.



**Figure 3.** A diagrammatic representation of the actual passage of the threads through the skin. After insertion of the needle, removal of the needle alone results in the thread remaining intact in the tissue.

of the needle and the other half on the outside. After insertion of the needle or cannula, removal of the needle or cannula alone results in the thread remaining intact in the tissue (Figure 3). Needle thicknesses of 18 to 31 gauge and threads with variable length and thickness are available. Appropriate thread length was selected depending on the skin length of the insertion area. Combination of cog and twin threads was used for lifting and rejuvenating purposes in all patients.

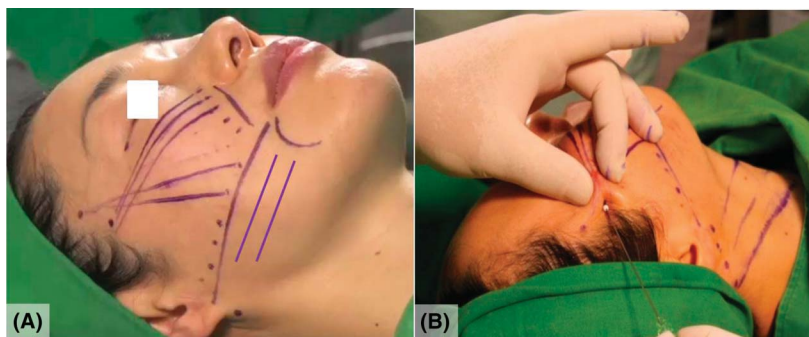
### Procedure

EMLA cream (AstraZeneca, Alderley Park, United Kingdom) was applied on the affected area for 1 hour before the procedure. The procedure areas were covered with Betadine. Local anesthetic nerve block was performed with 2% lidocaine with epinephrine (1:100,000) (Yuhan, Seoul, Korea).

The procedure site was selected to follow the thread insertion line depending on the patient's wrinkle status. The patient's skin, facial framework, and age were accounted for in designing the procedure, which was generally against the vector of sagging skin.

First, 5 points were made according to the nasolabial fold, and then 2 points were made along the hair line. A straight line was drawn from the edge of the lips to below the ear lobule (Figure 4). Then, they inserted 3.0 bidirectional cog threads on the nasolabial folds according to the straight line. Five threads were inserted subcutaneously on each cheek, with the vector direction against the sagging nasolabial folds. On each side, additional 2 twin threads were inserted lateral to the marionette line, parallel to the mandibular border.

To minimize edema and bruising, ice packs were applied. Oral cephalosporin was given up to 5 days after the procedure. Within the first 3 weeks after the procedure, abrupt actions and big movements of the perioral muscles such as yawning and laughing were prohibited, as was facial massage. Patients were encouraged to sleep in a supine position.



**Figure 4.** Basic guidelines for knotless PDO thread technique. First, 5 points were made according to the nasolabial fold, and then 2 points were made along the hair line. A straight line was drawn from the edge of the lips to below the ear lobule (A). Then, they inserted bidirectional cog threads on the nasolabial folds according to the straight line. Additional 2 twin threads were inserted lateral to the marionette line, parallel to the mandibular border (B).

## Results

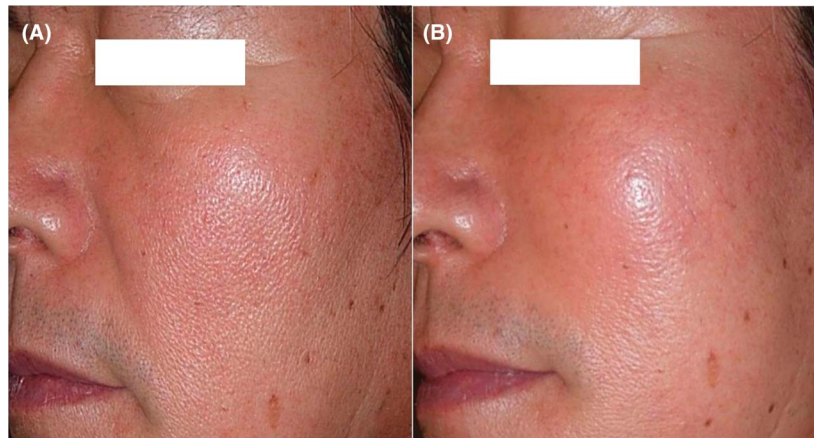
Patient clinical characteristics and outcomes are presented in Table 1. A total of 31 patients underwent knotless thread lifting using PDO over a 2-year period. Four were males and the rest were females, with an average age of  $44.13 \pm 11.02$  years. The follow-up period was 24 weeks. In 27 patients (87%), the self-evaluated result was considered satisfactory, including 19 patients (61%) with excellent and 8 (21%) with good results. The result was considered unsatisfactory for the remaining 4 patients (13%). Texture improvement was classified as excellent for 13 (41.9%), good for 9 (29.0%), fair for 8 (25.8%), and

poor for 1 (3.2%) patient(s). Lifting was evaluated as excellent for 11 (35.5%), good for 6 (19.4%), fair for 5 (16.1%), and poor for 9 (29.0%) patients. Polydioxanone thread lifting was better for skin texture improvement than for lifting, although there was no statistically significant difference ( $p = .139$ ) (Figure 5).

The most frequent complication was bruising, which happened in 29 patients (93.5%). Mild postprocedure swelling was observed in 28 patients (90.3%). Mild asymmetry was observed in 2 patients (6.5%). These side effects lasted for a maximum of 2 weeks and did not warrant treatment.

**TABLE 1. Postoperative Outcomes in Terms of Physician Assessment and Patient Satisfaction**

Patient no.	Sex	Age, yrs	Physician Assessment		Patient Satisfaction
			Texture Improvement	Lifting	
1	F	42	Excellent	Excellent	Excellent
2	F	57	Excellent	Excellent	Excellent
3	M	49	Excellent	Excellent	Excellent
4	M	53	Excellent	Good	Excellent
5	F	55	Excellent	Excellent	Excellent
6	M	62	Excellent	Excellent	Excellent
7	F	60	Excellent	Excellent	Excellent
8	F	52	Fair	Fair	Good
9	F	49	Good	Fair	Good
10	F	34	Fair	Poor	Good
11	F	32	Poor	Poor	Unsatisfied
12	F	42	Fair	Poor	Good
13	F	32	Good	Good	Excellent
14	F	54	Fair	Poor	Unsatisfied
15	F	38	Fair	Poor	Good
16	F	24	Good	Good	Excellent
17	F	57	Excellent	Excellent	Excellent
18	F	54	Excellent	Good	Excellent
19	F	30	Fair	Poor	Unsatisfied
20	F	34	Fair	Poor	Good
21	M	43	Good	Excellent	Excellent
22	F	24	Good	Fair	Good
23	F	53	Good	Fair	Good
24	F	45	Good	Excellent	Excellent
25	F	23	Excellent	Excellent	Excellent
26	F	47	Good	Poor	Excellent
27	F	41	Fair	Poor	Unsatisfied
28	F	37	Good	Good	Excellent
29	F	45	Excellent	Excellent	Excellent
30	F	47	Excellent	Good	Excellent
31	F	53	Excellent	Fair	Excellent



**Figure 5.** Preoperative and postoperative clinical photograph of a 53-year-old male patient: (A) initial; (B) 6-month follow-up.

## Discussion

In the late 1990s, Dr. Sulamanidze inserted bidirectional barbed sutures, manufactured with a non-absorbable polymer (polypropylene), into the subcutaneous plane of the face.<sup>2</sup> The possible complications of a nonabsorbable suture are palpation, migration, extrusion, and abnormal facial expression on animation.<sup>5</sup> Some patients express concern about the permanent presence of nonabsorbable threads in their facial tissue. For that reasons, more recently, absorbable barbed suture designs have become available.

Nowadays, various knotless thread lifting devices using PDO are popular in aesthetic clinics in Korea. The thread forms a V-shape with portions residing outside the needle/cannula and the other half inside the caliber. After inserting the needle or cannula, simply removing the needle or cannula results in the thread fixation inside the skin without anchorage or knots. This advantage facilitates quick and simple procedures.

Polydioxanone threads take about 6 months to be absorbed, longer than both Vicryl and Dexon. Accordingly, this thread has been used for wounds that require prolonged tensile strength. Given its monofilamentous form, PDO thread is less likely to harbor bacteria.<sup>10</sup> Ruff<sup>11</sup> suggested that PDO, a very slowly absorbed polymer, is sufficient to lift intact tissue satisfactorily with minimal concern about long-term

adverse effects. The review of cases in this study found that PDO thread is safe and effective for facial rejuvenation.

Jang and colleagues<sup>12</sup> showed in rats that myofibroblasts around cog threads placed under the skin play a role in fibrous tissue contracture 4 weeks after thread insertion. According to a histological evaluation of absorbable thread lift, a homogeneous fibrous capsule forms around the thread, preserving the traction and compactness of tissues. The dermal papillae have a greater thickness, indicating growth of the interstitial collagen component.<sup>9</sup> The improvements in fine wrinkles and marked pores observed in the patients could be explained by such changes in the dermis. Patient satisfaction and objective assessments indicated higher scores in texture improvement than lifting. Although the cogs were assumed to have lifting effect, it was not as powerful as that of the anchoring thread because of the lack of strong fixation. Further studies are needed to evaluate dermal remodeling by absorbable threads. The most common side effects the authors observed were mild bruising and edema. Erythema usually disappears within a few days. Facial asymmetry may persist for 1 to 2 weeks. The face usually becomes symmetric as time passes, so there is no need to rush for early corrections. Skin dimpling is a troublesome side effect, although it did not occur in this study. If thread is inserted too superficially, the dimpling can occur at the entry point of the thread. Skin rippling can persist for a long period, so inserting the thread at a proper depth is important. Infection,

scar tissue formation, and migration or total extrusion of the thread can occur.

The most important limitation of this procedure is that it is only indicated for a modest degree of facial soft tissue laxity. Paul<sup>5</sup> discussed the effect of selecting patients through experience in midface lifting using absorbable bidirectional barbed sutures. The most favorable anatomic characteristics for absorbable thread lifting are low body mass index, minimal fullness to the soft tissues, strong underlying bony projections to support the elevated tissue, and good skin quality. In the authors' experience, obesity with thick soft tissue results in poor outcomes. Therefore, appropriate patient selection is necessary for optimal outcomes. Insertion of 1 to 3 additional cog threads longitudinal to the cheek is effective for severely saggy skin. For additional marionette lines and chin lift, the use of an extra 3 to 5 cog threads perpendicular to the chin line gives more favorable results.

In conclusion, the technique using PDO thread did not require general anesthesia and avoided scarring, as an incision was not needed. The procedure was effective for uneven facial textures, slack midface, and minimal to moderate jowls in selected patients. The incidence of complications was low and not serious. Aesthetic procedures using PDO thread are a safe method for facial rejuvenation and lifting. Further studies are needed to optimize results and develop better methods.

## References

1. Nkengne A, Bertin C. Aging and facial changes—documenting clinical signs, part 1: clinical changes of the aging face. *Skinmed* 2013;11:281–6.
2. Sulamanidze M, Sulamanidze G. APTOS suture lifting methods: 10 years of experience. *Clinics in Plastic Surgery* 2009;36:281–306.
3. Atiyeh BS, Dibo SA, Costagliola M, Hayek SN. Barbed sutures “lunch time” lifting: evidence-based efficacy. *J Cosmet Dermatol* 2010;9:132–41.
4. Rachel JD, Lack EB, Larson B. Incidence of complications and early recurrence in 29 patients after facial rejuvenation with barbed suture lifting. *Dermatol Surg* 2010;36:348–54.
5. Paul MD. Barbed sutures in aesthetic plastic surgery: evolution of thought and process. *Aesthet Surg J* 2013;33:17S–31S.
6. Isse NG, Fodor PB. Elevating the midface with barbed polypropylene sutures. *Aesthet Surg J* 2005;25:301–3.
7. Wu WT. Barbed sutures in facial rejuvenation. *Aesthet Surg J* 2004;24:582–7.
8. Park TH, Seo SW, Whang KW. Facial rejuvenation with fine-barbed threads: the simple Miz lift. *Aesthetic Plast Surg* 2014;38:69–74.
9. Savoia A, Accardo C, Vannini F, Di PB, et al. Outcomes in thread lift for facial rejuvenation: a study performed with happy lift revitalizing. *Dermatol Ther (Heidelb)* 2014;4:103–14.
10. Tajirian AL, Goldberg DJ. A review of sutures and other skin closure materials. *J Cosmet Laser Ther* 2010;12:296–302.
11. Ruff G. Technique and uses for absorbable barbed sutures. *Aesthet Surg J* 2006;26:620–8.
12. Jang HJ, Lee WS, Hwang K, et al. Effect of cog threads under rat skin. *Dermatol Surg* 2005;31:1639–43.

---

Address correspondence and reprint requests to: Hwa Jung Ryu, MD, PhD, Department of Dermatology, Korea University Ansan Hospital, College of Medicine, Korea University, 516 Gojan-dong, Ansan, Gyeonggi-do 425-707, Korea, or e-mail: dermhj@naver.com